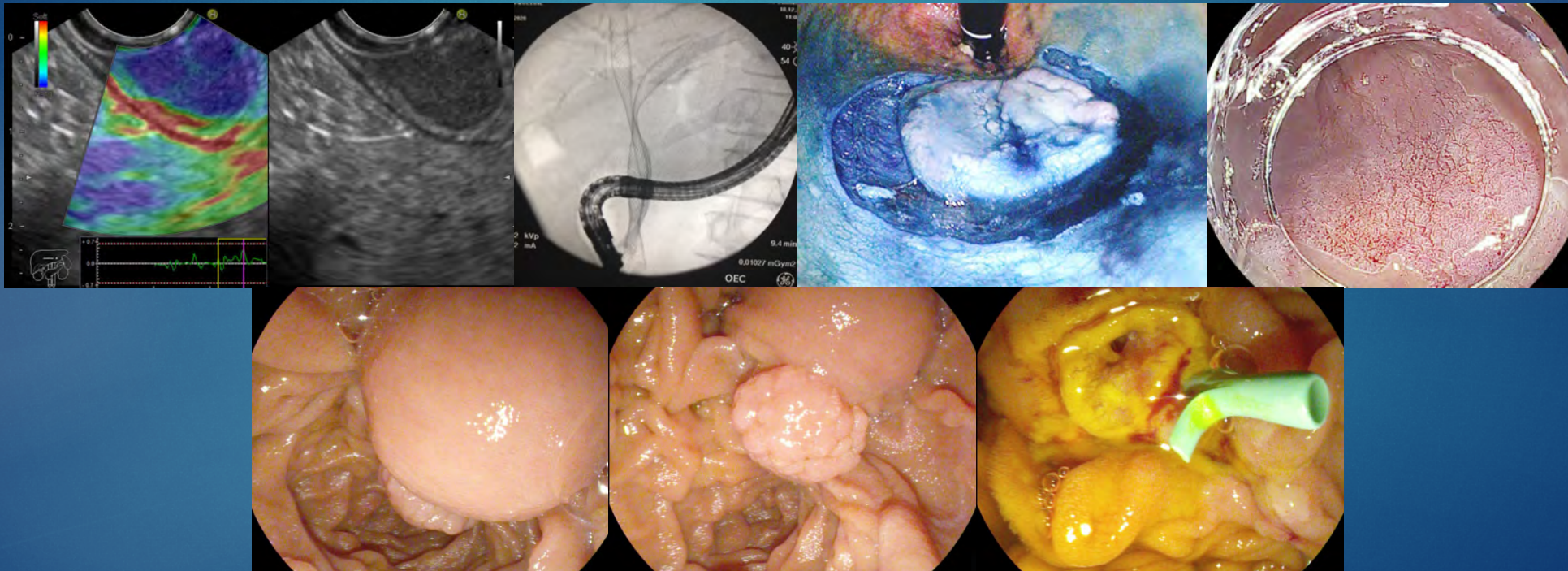


EUS-ENDO 2018

FOLLOW-UP CLINICAL CASES



INSTITUT PAOLI-CALMETTES

FOLLOW-UP OF THE PATIENTS EUS-ENDO 2018

- ▶ CASE 1 : Pancreatic cystic lesion typical of serous cystadenoma. MRI (01/2019) no modification of the lesion
- ▶ CASE 3: Zincker diverticulum, patient asymptomatic in dec 2018
- ▶ CASE 4: Biopsy with a moray forceps of a cystic lesion the tail of the pancreas. Results : pseudo-cyst, no malignancy. The pseudo-cyst was drained in october 2018 with 2 plastic pigtail stents of 7F. No complication, patient asymptomatic in dec 2018
- ▶ CASE 5 : Patient with a benign stenosis of an hepaticojejunal anastomosis treated by hepaticogastrostomy, impossibility to remove the metallic stent. Finally the metallic stent was removed the week after and a claibration was performed using 3 plastic doublepig tail stents of 7F.

FOLLOW-UP OF THE PATIENTS EUS-ENDO 2018

- ▶ CASE 6: Patient with an intrahepatic lithiasis treated by lithotripsy. Patient has relapsed the intra hepatic stones in the segment IV (january 21019). A surgery is scheduled
- ▶ CASE 7: EUS biopsy of a SMT, pathology examination showed a gastric adenocarcinoma. Patient is treated by chemotherapy
- ▶ CASE 8: pancreatic mass of 3 cm, EUS-FNB showed a pancreatic neuroendocrine tumor grade 1. Patient was operated and the resected specimen showed a neuroendocrine tumor pT2N1M1a grade 2.
- ▶ CASE 10: FTRD resection of the polyp developed in the appendix orifice, it was a serrated adenoma with low grade of dysplasia

FOLLOW-UP OF THE PATIENTS EUS-ENDO 2018

- ▶ CASE 12: Endoscopic ampullectomy showed an ampullary adenoma with high grade dysplasia. Endoscopic control in nov 2018 showed no residual tumor with normal biopsies
- ▶ CASE 13: Hepaticogastrostomy for a patient with a pancreatic head cancer with duodenal stent and previous biliary stent. No complication occurred. Patient received a chemotherapy, today stable disease, hepaticogastrostomy always functional
- ▶ CASE 14: Para-aortic mass of 3 cm, EUS-FNB showed a neuroendocrine tumor grade 1, PET-DOPA showed a NET of the small bowel with 2 liver M+. Patient is treated by Lanreotide

FOLLOW-UP OF THE PATIENTS EUS-ENDO 2018

- ▶ CASE 15: Endoscopic resection of a caecal polyp, pathologic examination showed an adeno-villous adenoma with low grade dysplasia
- ▶ CASE 19: esd for an antral lypolypoid lesion in a patient with an atrophic gastritis. Pathologic examination showed a adenomatous polyp with low grade dysplasia with negative margins (complete resection)
- ▶ CASE 20: Patiente with a gastric bass and biliary stones. A gastrogastrostomy was created using a 20 mm Axios stent with no complication. The week after an ERCP with sphincterotomy and stones extraction was performed throught the axios stent. The axios stent was removed and the communication closed using clips.

FOLLOW-UP OF THE PATIENTS EUS-ENDO 2018

- ▶ CASE 21: Patient with a pseudo-cyst in the head of the pancreas, he was treated the month after by a transpapillary stenting with a complete remission of the cyst
- ▶ CASE 22: Patient with a Barrett's esophagus with a nodule of high grade dysplasia. Complete resection with a duette system. Pathologic examination showed a Barrett's epithelium with high grade dysplasia with free deep margins. Follow-up in 01/2019 showed no relapse of the Barrett's epithelium